

## Protective Effect of Liv.52 Against Anti-cancer Chemotherapy in Rats

**Yadav, S.**, Demonstrator, and **Yadav, R.**, Assistant Professor,  
Department of anatomy and Biochemistry, Indira Gandhi Medical College, Shimla, India,  
and  
**Pande, B.S.**,  
Professor and Head, Department of Anatomy, Medical College, Rohtak, India.

### ABSTRACT

*The experimental study comprised of 30 albino rats out of which 10 acted as control and the rest of the animals were divided into two groups of 10 each. Histological changes in the liver tissue of the rats were studied after intraperitoneal administration of cyclophosphamide (30 mg/kg once only). With and without Liv.52 (200 mg/kg/day x 15 days) administration. When compared with the control group, cyclophosphamide produced severe fatty change, diffuse hepatocellular destruction, sinusoidal dilatation and congestion in rats. Hepatic changes reversed remarkably in the Liv.52-treated group and the total leucocyte count became near normal. In conclusion, Liv.52 was observed to exert a definite hepatoprotective effect against cyclophosphamide-induced hepatotoxicity. The study demonstrates that Liv.52 drops can be supplemented with all anti-cancer chemotherapies to decrease the side effects of drugs.*

**Keywords:** Cyclophosphamide, Rats, Hepatotoxicity, Liv.52, Histological, Leucocyte.

### INTRODUCTION

Cyclophosphamide is one of the most widely used antineoplastic and immunosuppressive drugs. It is also used in many non-neoplastic disorders like systemic lupus erythematosus, rheumatoid arthritis and nephrotic syndrome. Large quantities of the active cytotoxic metabolite acrolien and phosphoramidate mustard are produced in hepatocytes during its metabolism<sup>1</sup>.

Hepatotoxicity with the drug is reported in only a few reports in literature<sup>2,3</sup>. Cyclophosphamide-induced hepatotoxicity poses problems in persons with already compromised liver function, and there is an urgent search for a substitute to minimize hepatic dysfunction.

In view of the growing use of cyclophosphamide in non-neoplastic disorders and conflicting, contradictory reports of its effect on the liver, an experimental trial was conducted to establish the effect of the drug on liver parenchyma and also to document the utility of Liv.52 (multiherbal preparation) in preventing cyclophosphamide-induced hepatic dysfunction, if at all.

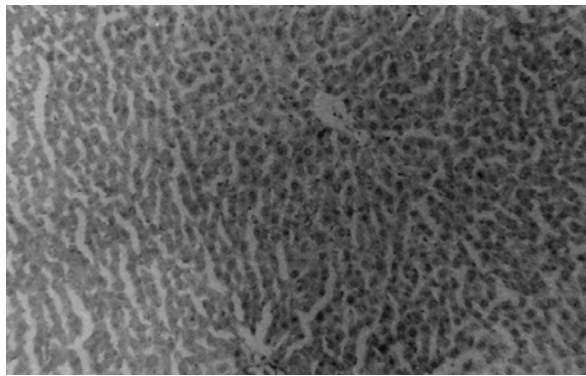
### MATERIAL AND METHODS

The experimental study comprised of 30 disease free albino rats of Wistar strain weighing 200-220 gms, out of which 10 acted as controls and the rest of the animals were divided into two groups of 10 each. All animals were maintained on standard rat feed and water ad-libitum. Under aseptic precautions, cyclophosphamide (Endoxan ASTA 100, 200 mg vials from Khandewal Lab. Ltd., Bombay) was administered intraperitoneally in a dose of 30 mg/kg body weight once only to the animals of test groups A and B. Animals of group B were in addition provided with Liv.52 drops

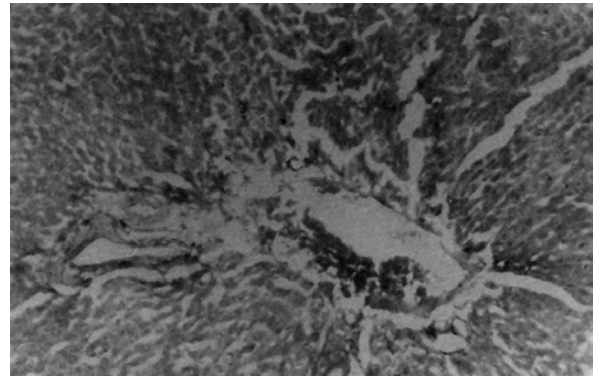
daily for 15 days. No drug was administered to the control group. A record of petechial hemorrhage in skin, color of urine, bleeding from orofaecal route and the number of animals dying during the experiment was kept. Slides for total leukocyte count were also made for all the groups. On day 15 under ether anesthesia, the livers were removed and processed by conventional paraffin sectioning and haemotoxylin and eosin staining. Changes in each group were compared with respect to overall findings. The protective effect of Liv.52 was evaluated with respect to the number of deaths, total leukocyte count and effect on hepatic parenchyma.

## RESULTS

Alteration in body weight and total leukocyte count was observed after the administration of cyclophosphamide. In the cyclophosphamide-treated group, the total leukocyte count was 5000 with a mortality rate of 30%. The liver showed disrupted lobular architecture, diffuse hepatocellular destruction, severe fatty change (Figs.1 and 2 ) almost involving the whole liver lobule with sinusoidal congestion and dilatation. The central vein was dilated with a mean diameter of 148.6 m.

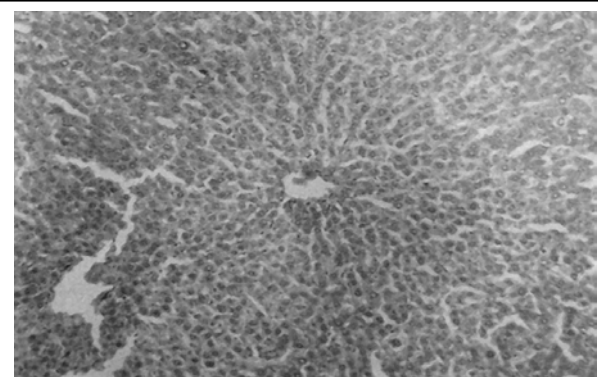


**Figure 1:** Control group. Photomicrograph of liver showing normal liver parenchyma of rat. H&E x 100.



**Figure 2:** Changes after administration of cyclophosphamide. Photomicrograph showing fatty change in liver parenchyma with dilatation & congestion of sinusoids. H&E x 100.

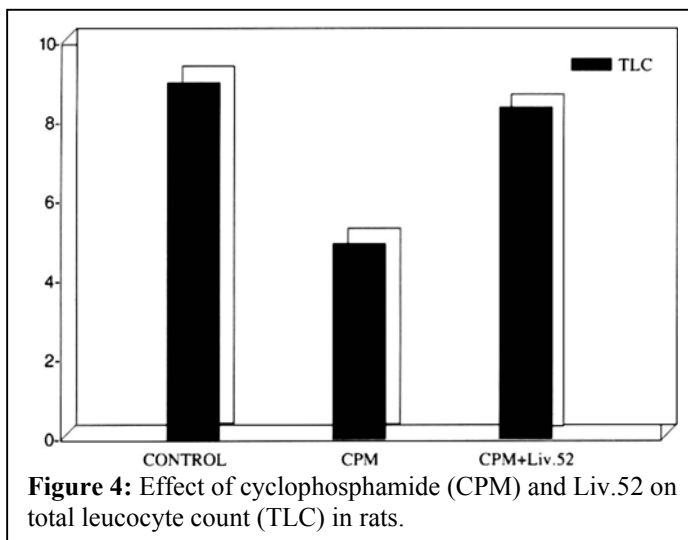
In the Liv.52-treated group, there was relatively less extensive fatty change as well as sinusoidal dilatation and congestion. Fatty change was diminished tremendously (Fig.3) but mononuclear infiltrate was more pronounced. Liv.52 post treatment reduced the leucopenia induced by cyclophosphamide in rats (Fig.4). Protection against mortality was observed in the cyclophosphamide-treated animals in the presence of Liv.52 drops. The central vein showed a mean diameter of 95m. In a nutshell, the Liv.52-treated group almost showed a reversal of hepatic changes induced by cyclophosphamide.



**Figure 3:** Changes after administration of cyclophosphamide with Liv.52 drops. Photomicrograph showing disappearance of fatty change and sinusoidal dilatation after administration of Liv.52 drops. H&E x 100

## DISCUSSION

Hepatotoxicity of cyclophosphamide is attributed to the generation of the cytotoxic metabolite acrolien and phosphoramidate mustard during its metabolism. Accumulation and binding of the cytotoxic intermediate to Cyt-P-450 of the hepatocytes renders it inactive and paralyzes the toxin neutralizing machinery of the hepatocytes manifested in the form of hepatocellular destruction. Reports of hepatotoxicity reported in literature are few, probably due to the huge functional reserve of the liver and also the regenerating



**Figure 4:** Effect of cyclophosphamide (CPM) and Liv.52 on total leucocyte count (TLC) in rats.

capacity of the liver parenchyma. Growing consumption of alcohol and other hepatotoxic drugs also compromises liver function, and in only such cases, we find hepatic dysfunction with use of cyclophosphamide. Our findings of severe fatty infiltration, diffuse hepatocellular destruction, sinusoidal dilatation and congestion are consistent with previous studies.

The reversal of fatty change and hepatocellular destruction with treatment with Liv.52 drops may be due to the liberation of –SH group of Cyt-P450, thereby showing a definite hepatoprotective effect against cyclophosphamide-induced hepatotoxicity. Increased survival in the Liv.52 treated group may also be due to the protection of the gastrointestinal tract and haemopoietic organs by Liv.52 against the toxicity of cyclophosphamide.

Cyclophosphamide administration leads to severe bone marrow depression manifested as marked leukopenia, bleeding tendencies and even hemorrhage. Severe immunosuppression occurs leading to decreased immunity and increased preponderance to severe infections manifested in the form of increased mortality rate. Liv.52 probably exerts its effect by protecting the blood forming organs against cyclophosphamide-induced hepatotoxicity. In a nutshell, Liv.52 appears to modify cyclophosphamide damage to liver and helps in the regeneration of damaged hepatocytes. The effect of Liv.52 against all other anticancer drugs needs to be evaluated before utilizing it with cancer chemotherapy.

## REFERENCES

1. Ohno, Y., Ormstad, K. Formation toxicity and inactivation of acrolien during biotransformation of cyclophosphamide as studied in freshly isolated cells from rat liver and kidney. *Toxicology* (1985): 57, 99.
2. Aubrey, D.A. Massive hepatic necrosis after cyclophosphamide. *Br. Med. J.* (1970): 3, 588.
3. Bacon, A.M., Rosenberg, S.A. Cyclophosphamide hepatotoxicity in a patient with systemic lupus erythematosus. *Ann. Intern. Med.* (1982): 97, 62-63.
4. Goldberg, J.W., Lidsky, M.D. Cyclophosphamide associated hepatotoxicity. *Sou. Med. J.* (1985): 78, 222.

5. Ylostalo, P., Kauppila, A., Joupila, P. Hepatic and adrenocortical function during cyclophosphamide stress therapy. *Acta Obstet. Gynecol. Scand.* (1973): 52, 299.
6. Daniel, B.M. Christian, C, Michel, M., Flix, R., Daniel, D. Anti-neoplastic agents and the liver. *Gastroenterol.* (1980): 78, 142.
7. Bajetta, E., Buzzoni, R., Giardini, R., Bonadonna, G. Liver assessment in women receiving adjuvant CMF chemotherapy. *Tumori* (1981): 67, 27.
8. Hagewald, G., Barenwald, G., Grick, A. Moritku elektonemi kroskopische befunde bei liberschaden durch arzneimittel (Choleretita zyklophosphamidphenylin dadlon). *Ges. Inn. Med.* (1968): 23, 321.
9. Shaunak, S., Munro, J.M., Weinbren, K., Walport, M.J. Cox, T.M. Cyclophosphamide-induced liver necrosis: A possible interaction with azathioprine. *Q.J. Med.* (1988): 67, 309.
10. Honjo, I., Suou, T., Nirayama, C. Hepatotoxicity of cyclophosphamide in men: Pharmacokinetic analysis res. Common. *Chem. Pathol. Pharmacol.* (1988): 61, 149.
11. Levin, S., Koss, L.G. Effect of a single dose of cyclophosphamide on rats: Electron microscopy of liver. *Am. J. Pathol.* (1971): 62, 159.